AdventHealth
2520 N. Orange Ave, Suite 200
Orlando, FL 32804

Non-Profit Org.
U.S. Postage
PAID
Permit 3635
Orlando FL

Care Navigation

Minimally Invasive Brain Surgery (MIBS)	407-303-7944	Alzheimer's Disease & Dementia	407-392-9237
Spine Center	407-303-9102	Normal Pressure Hydrocephalus	407-303-3282
Epilepsy & MEG	407-303-7520	MS	407-609-7002
Center for Sleep Disorders	407-303-1558	Neuromuscular	407-303-1123
Parkinson's Outreach Center	407-303-5295		

Learn More About These Programs

Endoscopic Endonasal Skull-Base Surgery

Brain Port Surgery

Deep Brain Stimulation

Updates in Neurology and Neurosurgery
AdventHealth Neuroscience Institute • Winter 2021 • Volume III, Issue II

Craig Brubaker, PhD
Vice President
AdventHealth Neuroscience Institute

AdventHealth Neurology and Neurosurgery Programs: Your First Choice for Challenging Brain and Spine Care Cases

This summer, *US News & World Report* once again named AdventHealth's Neurology and Neurosurgery programs amongst the top 50 in the country. As mentioned in the last edition of this newsletter, we have a vision and plan to become a national destination for patients from all over the globe. Our highly specialized physicians have not only helped address challenges with regional access to care but have also augmented concierge programming.

- Our **MRgFUS Program (magnetic resonance guided focused ultrasound)** launched in July and has been the vendor's strongest first volume at any site. This newest service in our Functional Neurosurgery Program provides a **non-invasive way to treat patients with essential tremors** and has become a care destination for patients from across the country.
- With the recent launch of the **VizAI Program**, our stroke neurologists, neuroradiologists, ED physicians, and interventional neuroradiologists are collaborating with Mission Control (AdventHealth's internal transport department) to **expedite the care of patients with large vessel occlusions**. In just two months, this team has achieved a decreased time to treatment.
- Our **Gamma Tile**, **Gamma Knife**, and **Minimally Invasive Brain Surgery Programs** continue to thrive and serve as differentiators for referring physicians and patients who need next-level quaternary care.
- Our subspecialty neurologists are being sought by patients and caregivers regionally and nationally, while our **stroke program has achieved AHA/ASA Gold Plus Target: Stroke Honor Role Elite Plus (DTN </= 45 min in 75% of eligible pts)**.
- Our neurologists, neurosurgeons, orthopedic spine surgeons, neurocritical care physicians, and more collaborate throughout the entire Central Florida Division via five different specialty governance meetings to ensure we are **continuing to standardize our care and improve the value equation (outcomes + experience/cost).**
- Our physician leaders are also **working to ensure best possible patient outcomes through multidisciplinary committees** such as our Tumor Board, Back Pain Taskforce, Normal Pressure Hydrocephalus Team, and Mortality & Morbidity meetings to name a few.
- Furthermore, our physicians' **active participation in ongoing clinical trials, original research, and numerous publications** contributes to the body of evidence in each of their specialties.

Learn more in this issue about the arrival of additional expert neurologists and surgeons who will further our capability to treat subspecialty disease and complex cases. Our goal is to serve as physicians' first choice for their most difficult surgical and medical cases to achieve the best possible outcome. We appreciate your partnership and collaboration on this journey.

In This Issue

AdventHealth
AdventHealthNeuroInstitute.com

George Simon, MD
Executive Director
Moffitt Cancer Center-AdventHealth Joint Clinical Research Unit

Moffitt Cancer Center-AdventHealth Joint Clinical Research Unit Increases Access to Early-phase Clinical Trials

Launched on the AdventHealth Celebration campus in the fall of 2020, the Moffitt Cancer Center-AdventHealth Joint Clinical Research Unit (CRU) is now fully operational and providing patients access to investigational early phase clinical trials. It is part of a larger partnership between Moffitt and AdventHealth focused on delivering the highest quality cancer care to patients throughout Central Florida.

Through the CRU, patients can access the latest cancer drugs, significantly enhancing the therapeutic armamentarium for patients with metastatic disease for whom treatment options may be limited. The CRU will be studying novel compounds across multiple platforms, including a wide range of rationally designed, target-specific drugs that have recently been developed in translational research laboratories. Current and future studies are exploring a number of potential new treatments in the following categories:

- **Antibody-drug conjugates** — These drugs are antibodies that are designed to attach to proteins on the surface of tumor cells. These antibodies carry a tumor-killing payload that is usually a chemotherapy moiety. The antibody attaches to the tumor surface protein, and the attached chemotherapy medication kills the tumor. This technology could improve tumor selectivity and reduce toxicity by minimizing damage to normal cells. Several antibody drug conjugates are already in common clinical practice, and several others are in various stages of investigation.
- **Novel targeted therapies** – Targeting the molecular machinery of cancer that promotes tumor growth has been a successful strategy, leading to the approval of several drugs for treatment of cancer patients. Not only are newer molecular targets being identified, but better drugs are being developed for older, well-known targets. Inevitably, resistance develops to targeted therapies, and newer drugs are being developed to specifically treat the emerging mechanisms of resistance. Some of these drugs will be evaluated in the CRU.
- **Novel immunotherapies** – Immunotherapies have radically changed the cancer therapeutic landscape. This is made possible by the discovery of specific 'checkpoints' that the tumors utilize to evade the immune system. Antibodies have been developed to 'block' these checkpoints, allowing the immune system to identify and destroy the tumors. However, 'newer' checkpoints have been identified, and antibodies have been made to these novel checkpoints. Some of these newer immunotherapies are currently being studied in the CRU.
- **Bispecific antibodies** – These antibodies have the ability to bind to two different proteins at the same time. By doing this, the antibodies bring cancer-killing T-cells in close proximity to cancer cells, facilitating the T-cells ability to kill the cancer cells. Other antibodies enhance T-cell function, augmenting their ability to kill cancer cells.
- **Epigenetic therapies** — By epigenetic mechanisms (i.e., by chemically modifying DNA without structurally changing it), cancer cells have essentially re-wired their genetic program to give themselves the growth advantage. Epigenetic therapies aim to reprogram cancer cells to a more normal state by altering the chemical modifications made by cancer cells. This leads to reduced cancer growth and even the death of cancer cells in some instances.
- **Therapeutic viruses** — Viruses naturally know how to infect human cells. This ability can be harnessed for therapeutic gain. The genome of the virus can be altered in such a way that once it infects a human cell, it cannot replicate and establish an infection. The genome of such 'replication-incompetent' viruses can be further modified to carry a genetic 'payload' that alters tumor behavior favorably or even programs it to die.

In addition to these platforms, future studies will explore **cellular therapy approaches** where live cancer-fighting cells are used as therapy. Several of these are currently being used in hematological malignancies and are also being evaluated in solid tumors. **Novel RNA vaccines against cancer** are another therapeutic platform that is likely to be explored in the CRU. Similar in design to the COVID vaccines that are in general use today, RNA vaccines were initially being developed to treat cancer before the emergence of the pandemic. Now they are likely to soon be offered as anti-cancer therapies through the CRU.

The drugs that we currently use as standard of care were essentially developed in the 1980s and 1990s. Most were made from various plant parts (paclitaxel, docetaxel, vinorelbine, etc.) or extracted from nature (platinum-based drugs). Compounds with cancer-killing potential were then exposed to various cancer cell lines, or human trials were conducted to determine which cancers these drugs could most likely effectively target. Often, the mechanism of action of these drugs was poorly understood or elucidated well after the drugs were in clinical use. Hence, drug development in the 1980s or 1990s involved trial and error. The drug was developed and then often had limited efficacy. For example, docetaxel had a single-agent response rate of approximately 10% in the second-line treatment of patients with advanced non-small cell lung cancer (NSCLC). The typical response rates seen in the Phase I studies conducted in the 1980s or 1990s were in the vicinity of 4%.

Because of the targeted nature and rational design of the drugs being developed today and because of our improved understanding of the molecular mechanisms of cancer in general and specific molecular targets in particular, the 'trial and error' or the 'guess work' in early drug development has been substantially reduced.

Most of the drugs being developed today are chemicals that were designed from the ground up in the laboratory (and not obtained from nature) to inhibit a specific receptor or molecular pathway that is known to promote cancer. Thus, as these drugs are being designed and studied, we know how these drugs work and in which kind of cancers they are likely to work. Therefore, we tend to see better responses and efficacy in early drug development today than was historically seen in the early-phase studies of the 1980s and 1990s. A recent paper from a major university in the United States reported a response rate of 26% in patients enrolled to early phase studies which is far better than the 4% response rates reported in the older studies and potentially better than the 'standard' drugs used today (10% response rates seen with docetaxel in the second-line treatment of patients with advanced NSCLC). Furthermore, not only are these rationally designed and molecularly targeted drugs likely to be more effective, they are also likely to be less toxic than many of today's standard drugs, especially given the 'shot-gun' mechanism of cancer-killing many of the drugs developed in previous decades espoused.

All of these insights make an argument for incorporating early-phase clinical trials early in the treatment course of the disease (for example, as second-line or third-line therapy or even as first-line therapy in some cases) rather than reserve them for when all the standard options are exhausted. In fact, referral for a clinical trial should be considered every time a change in treatment is being considered. This will not only increase the number of therapeutic options available to physicians to treat their patients, but will also reserve standard treatment options for later use if the need arises. It will also allow for the retention of patients in the Central Florida region since one of the most common reasons patients leave their county or state to access care elsewhere is because of the non-availability of treatment options closer to home. More importantly one of the most common reasons patients don't enroll in clinical trials is that their physician did not offer them as an option.

By offering a menu of state-of-the-art early phase clinical trials to patients, the Moffitt-AdventHealth CRU aims to enhance patient access, convenience and retention.

For more information about the Clinical Research Unit and its current clinical trials, contact George.Simon.MD@AdventHealth.com.

Cory Hartman, MD
Spinal Neurosurgeon
AdventHealth Neuroscience Institute

Improving the Care of Back Pain Patients

It has been well established that back pain is a huge burden not only on health care, but on the economy as a whole. In 2011, the National Institutes of Health (NIH) reported the total incremental cost of health care secondary to pain ranged from $261 to $300 billion while the total financial cost for society due to increased healthcare cost and lost productivity ranged from $560 to $635 billion. While pain may be caused from a number of regions of the body, a NIH study showed that over a three-month period, 28% of adults reported pain in the lower back region. Previous studies have indicated there are at least 2.6 million visits for low back pain to U.S. emergency rooms each year.

AdventHealth and its physician partners established the **Spine Care Center** to help patients navigate the complex healthcare environment. Within this Center, the **Back Pain Task Force was established to improve the quality of care for patients who present to the emergency room for back pain**. It applies a multidisciplinary approach, including pain management, physical therapy, physiatry, neurosurgery and orthopedics, to treat patients who are discharged from the emergency room with an ICD-10 of back pain. Patients who do not have any red flag symptoms or signs related to their back pain are given the opportunity to have the Spine Center help coordinate their care following discharge from the emergency room.

Eighteen Central Florida AdventHealth campuses have been on-boarded into the Spine Center. The Center includes four non-clinical intake coordinators and three RN navigators plus a RN Spine Center manager. They all work under the Spine Center director and perform the following functions:

- Educate patients on diagnosis, treatment and rehabilitation options
- Facilitate scheduling of additional testing as needed
- Coordinate scheduling and treatment
- Communicate with referring physicians
- Refer patients to appropriate providers based on their individual circumstances
- Navigate patients through the surgical process
- Follow up with patients after discharge from the hospital

One of the key components of this program is to ensure that each patient has an appointment with the referring provider within 14 days. This helps eliminate patients returning to the emergency room and prevents care delays.

Here are a few Spine Center highlights from the past 12 months:

- The Central Florida Division has had 15,603 patients referred to the Spine Center with 14,930 of those presenting through the emergency room. Patients may elect to proceed through the Spine Center versus following up with their primary care physician.
- The Spine Center helped coordinate 5,768 patients through the healthcare system. Overall, 47.3% of the patients were referred to pain management for conservative management of their pain, 35.6% of patients went for surgical intervention, and 14% of patients were treated with physical therapy.
- Ultimately, 256 patients referred to the Spine Center, and 131 patients who received coordinated care underwent surgical intervention.

The AdventHealth Spine Center and specifically, the Back Pain Task Force, has established a multidisciplinary approach to help facilitate care pathways for patients suffering back pain. Not only has this improved the quality of care for these patients, it has also decreased the burden on the emergency rooms and urgent care centers across Central Florida. The heart of the program remains coordination of the RN navigators. As the Central Florida population continues to increase, the Back Pain Task Force will continue to expand and improve the high-quality, cost-effective care for patients with back pain.

For more information, please visit AdventHealthNeuroInstitute.com.

AdventHealth Epilepsy Center Reports Experience on Laser Interstitial Thermal Therapy (LITT) for MRI-negative Insular and Cingulate Epilepsy

Elakkat Dharmaraj Gireesh, MD
Neurologist
AdventHealth Neuroscience Institute

Study Published in *Journal of Neurosurgery*

Epilepsy is a central nervous system (neurological) disorder in which brain activity becomes abnormal, causing periods of unusual behavior, sensations, loss of awareness and sometimes convulsions. The long-term effects of epilepsy include injuries, increased intensity and frequency of seizures over time, and memory problems. There are around 3.4 million people with epilepsy nationwide, which is around 1% of the US population, and 30-35% of these patients have drug-resistant epilepsy (DRE).

Epilepsy surgery is an option for some of the patients whose seizure focus is established through presurgical evaluations. Identifying the seizure onset zone can be challenging, especially when the MRI is negative for any definite abnormality that can explain the seizures. In those scenarios, intracranial electroencephalography (EEG) monitoring is used as a strategy for identifying seizure onset zones, with either surface electrodes or with stereo EEG (sEEG). Stereo EEG is a minimally invasive procedure that helps the epileptologist to find the seizure onset zones. During the sEEG, small wires with contacts record electrical activity on the surface and deeper locations of the brain. Neurosurgeons will put these wires in the brain using a robotic operating surgery assistant (ROSA) in the operating room. ROSA enables the neurosurgeon to place the wires precisely and efficiently, thereby reducing the operating time and complications.

Patients with drug-resistant epilepsy can be treated with surgical strategies designed to remove the seizure onset zone or to disrupt the epileptic network. Currently, long-term seizure control after epilepsy surgery ranges from 34-56% for epilepsy arising from locations other than the temporal lobe. Failure of adequate control has been attributed to inability in identifying the epileptogenic zone(s) and inadequate or inaccurate surgical interventions.

The surgical options for epilepsy patients include resection of the seizure onset zones, disconnection of the seizure onset zones, laser interstitial thermal therapy (also called laser ablation or LITT) or neurostimulation strategies (responsive neural stimulation or deep brain neurostimulation). LITT is a minimally invasive surgical option for people with drug-resistant epilepsy, mainly for those with focal epilepsy, who have seizures originating in one particular region of the brain. In this procedure, the surgeon navigates a laser wire toward the area in the person's brain that is identified as the source of seizures, with magnetic resonance imaging (MRI) guidance. Once the laser wire is placed in the area of interest, heat energy from the laser wire is used to destroy the region.

We have been using the sEEG with robotic guidance and LITT in appropriately selected patients since 2014. The patients for this procedure were selected through the presurgical work-up, including scalp video EEG evaluation; MRI brain, including diffusion tensor imaging (DTI) sequences; attempted ictal single-photon emission computerized tomography (SPECT); positron emission tomography (PET); magnetoencephalography (MEG); and neuropsychological evaluation to localize the epileptogenic zones.

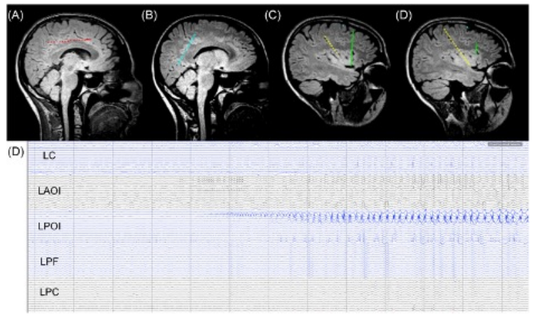

When insular or cingulate cortex are suspected as seizure onset zones, invasive monitoring of these structures with sEEG would improve epilepsy management. Neither the insula nor the cingulate can be easily monitored using subdural electrode arrays. Attempts to monitor these structures using combinations of subdural and depth electrodes have achieved inconsistent success in the past. Therefore, sEEG appears to be significantly helpful in localizing seizure onset zones in patients suspected to have insular and cingulate epilepsy.

In the patients we reviewed in this study, sEEG electrodes were implanted with robotic guidance and monitored in the neuro intensive care unit (ICU) in order to capture typical seizures. Surgical intervention at insula or cingulate regions was recommended based on these evaluations. The fact that the insula lies deep within the sylvian fissure and is adjacent to critical structures, including the internal capsule, makes it difficult to approach using conventional surgical strategies. In the dominant hemisphere, the insula is covered by eloquent frontal, temporal and parietal opercula, and open surgery options in this region risks language impairment for the patient. The cingulate gyrus is challenging to access surgically because of its location along the deep medial surface of the brain. Given these challenges, LITT provides definite advantages for optimal interventions in these brain regions, minimizing the risks compared to an open surgery approach.

In our study involving the patients suspected of having insula and cingulate onset epilepsy who underwent intracranial monitoring and LITT of the insula and cingulum, 67% achieved complete seizure freedom, and all patients had a favorable response with worthwhile improvement in seizures. There were no permanent neurological or neuropsychological deficits in this group of patients. Hemorrhagic complications were noted in a small group of patients with no long-term sequelae. The complication rates associated with LITT in these locations were comparable to those following open insular resection. A dominant hemisphere insular or cingulate seizure onset zone is not a contraindication to LITT. Our experience suggests that sEEG followed by LITT is a reasonable treatment option for drug-resistant epilepsy originating from these difficult-to-access regions of the cerebral cortex, particularly for patients with non-lesional epilepsy. Potential risk of hemorrhage should be considered in the decision-making process.

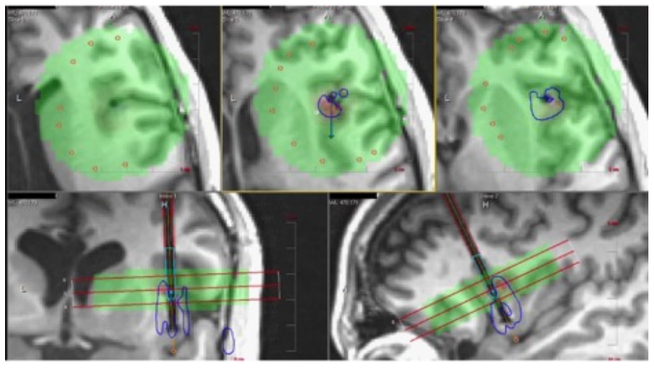

For more information, please visit AdventHealthNeuroInstitute.com.

Pitfalls in Motion Preservation Spine Surgery: Correction of a Complex Spinal Deformity Related to Failure of Cervical Artificial Discs

Kelvin S. Wilson, MD, FAANS
Neurosurgeon
AdventHealth Neuroscience Institute

Anterior cervical discectomy and fusion (ACDF) has been the "gold standard" for surgically treating cervical disc disease for more than 40 years. It has been used to treat a number of pathologies, including cervical radicular and axial neck pain related to herniated discs and instability related to advanced degenerative disc disease and cervical spine trauma.

Although ACDF has stood the test of time by providing good, reliable, and reproducible results with a low complication profile, questions about the loss of cervical mobility and the increased risk of additional needed surgery in the future has pushed medical device companies to develop cervical artificial discs (CAD).

Cervical artificial disc replacement surgery is considered a "motion preserving" alternative to ACDF as the artificial discs are engineered to mimic the biomechanical properties of the body's natural intervertebral discs. Potential advantages of CADs include faster recovery and return to work, lower risk of developing problems at the adjacent level, and by extension, lower risk of requiring additional surgical intervention.

Over the past five years I've performed a procedure mix of approximately 60:40 ACDF to CAD. In carefully selected patients, I've found CAD to be a phenomenal alternative to ACDF and an invaluable tool in my quest to provide my patients with safer, more efficient and less invasive surgical solutions.

Relative contraindications to CAD include loss or reversal of the normal cervical alignment, instability at the index or adjacent levels, diminished bone density, and isolated axial neck pain.

CASE STUDY

I present the case of a 50-year-old retired service member who presented with rapidly progressive axial neck pain worse with flexion and a constellation of symptoms known as cervical myelopathy (loss of hand dexterity, difficulty ambulating and new onset urinary incontinence). Three years prior, while on work assignment in Germany, he developed cervical radiculopathy and after failure of conservative therapy, underwent placement of two cervical artificial discs at adjacent levels. He reported that he initially did well for a year but then began to develop severe axial neck pain that progressed slowly until three months prior to seeing me in clinic.

Miraculously, the patient walked into my clinic under his own power, albeit with a classic spastic gait. Detailed neurological assessment corroborated a diagnosis of severe cervical myelopathy. X-rays revealed a complex and advanced kyphotic deformity of the cervical spine secondary to fracture and subluxation of the upper implant, fracture and deformity of the adjoining vertebral body, and marked subsidence of the lower implant (A). MRI revealed severe spinal cord compression with near complete obliteration of the spinal canal.

Correction of this complex pathology required an equally complex solution. Although like most spine surgeons practicing today, I've focused a large part of my practice on minimally invasive techniques, this correction required extensive multi-level anterior corpectomy with use of intraoperative dynamic traction, anterior reconstruction with an expandable cage, as well as posterior supplemental fixation with a rod/screw construct all during the same operation.

The result, seen in figure B, demonstrates C4, C5, C6 complete corpectomies with a partial corpectomy of C7, anterior plating from C3-C7, and posterior fixation from C2-T2 with multiple osteotomies to facilitate correction. Immediate postoperative recovery included one day in the ICU, followed by two days on the med-surg unit. The patient was discharged home on POD #3 with significant improvement in his hand dexterity, ambulatory power, and resolution of his urinary incontinence. One-year post-op x-rays (Figure C) showed a stable construct without hardware changes, and more importantly, the patient happily reported the complete resolution of all of his preoperative symptoms.

For more information, please visit AdventHealthNeuroInstitute.com.

FIGURE A

FIGURE B

FIGURE C

Walter R. Morgan, MD
Stroke Medical Director
Comprehensive Stroke Center at AdventHealth Celebration

Case Study: Complex Stroke Case Demonstrates Expanded Neurological Care at AdventHealth Celebration

The outcomes of a program's most complex cases often define that program's quality. Given the recent addition of neurosurgery, neuro-intervention, and neurocritical care to AdventHealth Celebration, it was only a matter of time before our hospital would encounter such a challenge.

A 39-year-old gentleman with no significant past medical history arrived at our Palm Parkway stand-alone Emergency Department with a complaint of dizziness that began while working out at the gym. The patient was evaluated by the acute stroke neurologist and subsequently diagnosed with a cerebellar stroke. The patient received thrombolysis with tPA. Advanced imaging with CT angiogram revealed a vertebral artery dissection but no occlusive thrombus of the basilar artery. The patient was then transferred to the recently expanded NeuroIntensive Unit (Neuro ICU) at AdventHealth Celebration.

Bilateral cerebellar strokes with edema and mass effect on the 4th ventricle.

Approximately 12 hours after admission, the patient experienced a decline in his mental status, prompting a stat non-contrast computed tomography (CT) of the head which revealed bilateral cerebellar strokes. The associated cytotoxic edema resulted in significant mass effect on the 4th ventricle and early hydrocephalus.

The patient was then taken to surgery for an emergency sub-occipital decompressive craniotomy and placement of an extra ventricular drain to relieve the pressure.

Following the craniotomy, an emergent diagnostic angiogram was performed to evaluate for any residual thrombus of the basilar artery. The cerebral angiogram did not reveal a basilar thrombus but did confirm the aforementioned dissection. The patient was then placed on hypertonic therapy where he was monitored both clinically and with serial imaging. The patient was also monitored with continuous video electroencephalography (EEG) but no had no seizure activity.

CT post suboccipital craniotomy.

Over the ensuing days, the patient's neurological exam improved, and after one week, he was able to be extubated. Follow-up imaging demonstrated improvement in the edema.

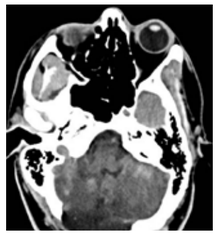

Follow-up CT with improvement of cerebellar edema.

After a few more days of observation in the Neuro ICU, the patient was downgraded to the Progressive Care Stroke Unit and placed on long-term anticoagulation for further stroke prevention related to the dissection. He was subsequently discharged to inpatient rehab and eventually, home.

The expansion of a comprehensive stroke program at AdventHealth Celebration was planned over several years with intensive participation from the clinical team and administration. In less than one year, the program has been able to deliver a high level of quality care to a number of stroke patients. This case is an excellent demonstration of the importance of having multiple service lines working together to reach a positive outcome in what would have been a fatal stroke. It also demonstrates that with strategic planning and administrative support, the development of a robust comprehensive stroke program can be achieved in a short time and still provide high-quality care.

We are excited about the expansion of our neurological and neurosurgical services at AdventHealth Celebration and the impacts these services will continue to have on our community.

For more information, please visit AdventHealthNeuroInstitute.com.

Herbert Newton, MD
Medical Director
Neuro-Oncology Program
AdventHealth Cancer Institute

Understanding the Causes of Gliomas — New Findings on Environmental and Sex-specific Molecular Signatures

Glioma is the most common type of malignant brain tumor with an incident rate of 4.67 per 100,000 population as reported by the Central Brain Tumor Registry of the United States (CBTRUS). Because glioma has significant morbidity and mortality rates, researchers continue to conduct epidemiology, genetics and neuropathology studies to better understand its causes and risk factors and to begin to identify potential new targeted therapies that could improve patient outcomes. A recent study published in *Neuro-Oncology* by researchers from Yale University, Brigham and Women's Hospital and Emmanuel College revealed three new findings about the causes of gliomas:

- **Cancer-causing genetic mutations of glioma result more from endogenous factors than from exogenous factors**. This finding is consistent with numerous previously published data and corroborates that information. It is important in that we now don't have to focus on mitigating numerous environmental factors involved in the etiology of gliomas and particularly, glioblastoma multiforme (GBM).
- **Mutations in the phosphoinositide 3-kinase (PI3K) pathway are differentially selected in males and females**. The PI3K signal transduction pathway has been noted to be important in gliomagenesis for some time. This data corroborates that as well and gives further impetus to investigate tertiary and quaternary drug development that can inhibit the various components of the pathway.
- **Haloalkanes, a class of chemicals used in flame retardants, fire extinguishers, refrigerants, solvents and pharmaceuticals, may pose a rare environmental risk, leading to some cases of glioma, especially in males.** This information is fairly new and unique and will be important moving forward in trying to find new ways to mitigate exposure to these chemicals in the vulnerable groups (e.g., firefighters).

Over the years, numerous epidemiological studies have found males to have a 50% greater risk of diagnosis of glioma as well as lower survival rates than females. An increased risk of glioma in firefighters has also been noted. In addition, medical researchers have explored the role of tumor molecular markers and have begun incorporating the presence or absence of isoforms 1 and 2 of isocitrate dehydrogenase (IDH1/2) mutations into glioma tumor classification.

Researchers for this most recent study evaluated whole-exome sequencing data from 1,105 adult glioma tumor samples secured through the National Cancer Institute's Genomic Data Commons Data Portal and the GLASS Consortium. They found that the predominant molecular signature across all glioma categories, Cosmic signature #1, is strongly associated with aging. Their additional findings regarding sex-specific mutations in the PI3K pathway and the increased environmental risk posed by haloalkanes could open the door for new research on potential preventive measures and targeted treatment approaches.

For more information, please visit AdventHealthNeuroInstitute.com.

Ryan Mizell, MD
Neurologist
Medical Director Neuroimmunology
AdventHealth Neuroscience Institute

Case Study: Addressing Challenges in Multiple Sclerosis Diagnosis

Multiple sclerosis (MS) is a chronic, neurologic disease affecting nearly one million people in the United States and potentially causing severe disability. Though there is no cure, the advances in medications for MS have shown to be effective in preventing relapses and lesions on MRI of the central nervous system. Despite advanced imaging techniques, MS can be a difficult disease to diagnose.

A young female presented to clinic for assessment. She first had symptoms of numbness that lasted over several months. After undergoing MRI of the brain in 2019, she was not given a diagnosis.

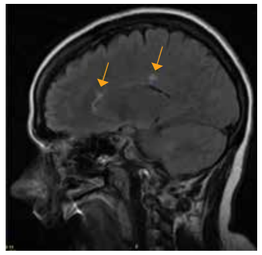

2019 Brain MRI

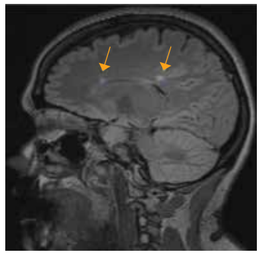

2021 Brain MRI

In 2021, she began to develop numbness in her right arm and hands that progressed over one month to encompass her left arm and hands. She was seen at AdventHealth Neurology in Winter Park and underwent further testing that included MRI of the brain, cervical and thoracic spine. As her previous images were compared to her current images, she was found to have previous lesions in the brain located in the periventricular and infratentorial region of the brain, which are common locations for lesions of MS.

She had an actively enhancing juxtacortical lesion present in the left temporal region.

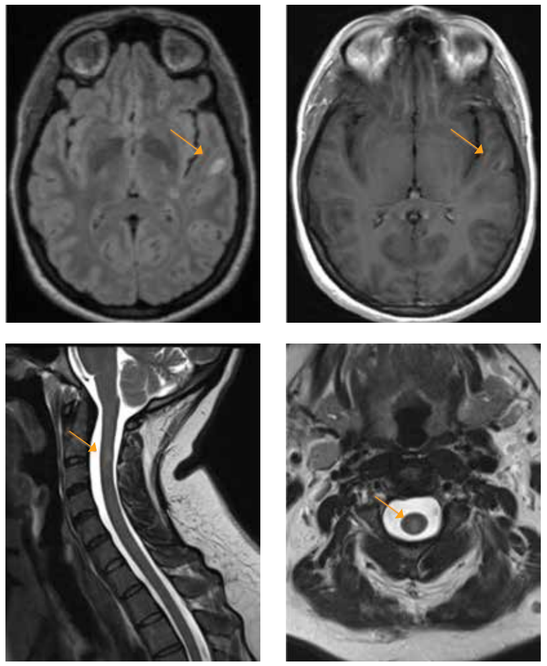

She underwent analysis of her cerebral spinal fluid, for which she had 15 oligoclonal bands, a test that is positive in patients with MS approximately 90-95% of the time.

After discussing the diagnosis, further conversations involved the recommendations to start a medication to treat MS with the goal of preventing relapses, new lesions, and disability. After a thorough discussion of the risks and benefits of different medications, she agreed to start ocrelizumab, a medication that is infused every six months and is used to treat patients with relapsing-remitting MS and primary-progressive MS. She continues to follow at the AdventHealth Neurology in Winter Park and remains relapse free on her current therapy.

For more information, please visit AdventHealthNeuroInstitute.com.

AdventHealth Neuroscience Institute Welcomes New Physicians

Kayla Handy, MD

Board-certified Neurologist
Board-certified Headache Specialist

Kayla Handy, MD, is a board-certified neurologist and headache specialist in Champions Gate. She specializes in migraine, tension-type headaches and cluster headaches as well as idiopathic intracranial hypertension, trigeminal autonomic cephalgias and neuralgia, occipital neuralgia, atypical facial pain, and spontaneous intracranial hypotension. Her passion for treating headaches stems from seeing family members suffer through disabling migraines. Dr. Handy completed a fellowship in headache medicine at Duke University Medical Center after completing her neurology residency at Wake Forest Baptist Medical Center. She earned her undergraduate and medical degrees at the University of Oklahoma.

Wissam Elfallal, DO

Neurosurgeon

Wissam Elfallal, DO, is a neurosurgeon in Daytona Beach, specializing in craniotomy for tumor treatment, surgery for peripheral nerve disorders, Chiari malformation surgery, evaluation and treatment of normal pressure hydrocephalus (NPH), aneurysms and AVMs, brain and spine tumors, traumatic injuries of the brain and spine, minimally invasive spine surgery, and complex spine disorders of cervical, thoracic and lumbar spine disease. He completed his neurosurgery residency at the Beaumont Health System in association with Oakland University School of Medicine and spent three years as Chief Resident. Prior to that, he completed an internship in neurological surgery at Garden City Hospital and his medical degree from the Michigan State University College of Osteopathic Medicine. He is a member of the American Association of Neurological Surgeons and the Minimally Invasive Neurological Society.

Valeria C. Baldivieso Hurtado, MD

Geriatrician, Medical Director Memory Care AdventHealth Neuroscience Institute

Fluent in English and Spanish, Valeria C. Baldivieso Hurtado, MD, is a board-certified physician in Winter Park who focuses on senior memory care and well-being, including Alzheimer's disease and other dementias as well as major depressive disorder, anxiety and insomnia. She completed a Geriatric Medicine Fellowship at Jackson Memorial Hospital in Miami after completing her Family Medicine residency at Mayaguez Medical Center in Mayaguez, Puerto Rico. She completed her internship at Santa Maria Chapalita Hospital in Guadalajara, Mexico, and earned her medical degree from the Autonomous University of Guadalajara.

Carlos Guerrero, MD

Neurologist

Carlos M. Guerrero, MD, is a general neurologist serving Celebration and the surrounding area. Fluent in English and Spanish, he completed his internship and neurology residency at the Medical University of South Carolina in Charleston, South Carolina, where he developed special interests in stroke, headache, epilepsy and neurodegenerative disorders. Dr. Guerrero earned his medical degree from The Medical College of Georgia in Augusta and his undergraduate degree in applied physiology and kinesiology from the University of Florida.

Magdalena Stepien, MD

Board-certified Neurologist

Magdalena Stepien, MD, is a board-certified neurologist with offices in Apopka and Winter Park. She has advanced fellowship training in electroencephalography (EEG) and epilepsy and special interests in epilepsy in females, EEG monitoring and vagal nerve stimulation (VNS)/responsive neuro stimulation (RNS) management. A Phi Beta Kappa honors graduate of the University of Chicago, she earned her medical degree at Chicago's Rush University and continued there for her internal medicine internship, neurology residency, and neurophysiology fellowship. Fluent in English and Polish, Dr. Stepien is a member of the American Academy of Neurology.

Jesna Sublett, MD

Fellowship-trained Spine Surgeon

Fluent in English, Hindi and Malayalam, Jesna Sublett, MD, is a neurosurgeon serving the Daytona Beach area. She has a special interest in minimally invasive spine surgery, completing a fellowship at the Semmes-Murphey Neurologic & Spine Institute. Prior to that, she completed her neurosurgery residency at the Geisinger Health System in Danville, Pennsylvania, capping her tenure there as Chief Resident. Born and raised in India, she earned her medical degree at the University College of Medical Sciences, Delhi University.

Michael P. Bellow, MD
Neurosurgeon
AdventHealth Neuroscience Institute

Case Study: Flow-diversion Advances in Minimally Invasive Brain Aneurysm Surgery

A 72-year-old gentleman received repeated imaging to look for signs of recurrence after left-sided brain surgery to remove a tumor. He remained in remission, but unfortunately, a left middle cerebral artery (MCA) brain aneurysm was identified. Over the years, the aneurysm grew, suggesting it was unstable and probably at a higher risk of rupture. Four factors made his situation more complex than average:

1. His left brain was the dominant hemisphere responsible for his ability to speak and understand speech; the aneurysm involved the left MCA which carries oxygen and nutrients to this critical brain.
2. The aneurysm was fusiform and involved the entire 360 degrees of a segment of this left MCA (Figure 1).
3. The aneurysm was located far downstream, making access through the tortuous arteries more difficult.
4. A second brain surgery at the same location would place him at higher risk for (a) brain injury due to scarring from the first procedure and (b) poor wound healing.

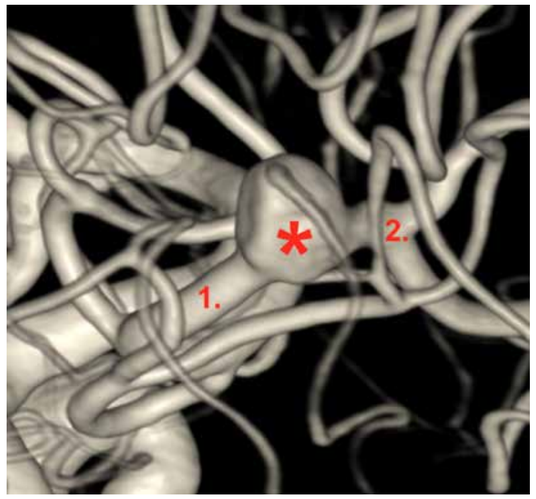

Figure 1. Image from the patient's 3D angiogram demonstrating a fusiform aneurysm of the left MCA labeled with a red asterisk, "*." The proximal left MCA carrying blood towards the aneurysm is labeled with a red number one, "1." The distal left MCA carrying blood away from the aneurysm and bifurcating to feed critical brain is labeled with a red number two, "2."

Up until 10 years ago, minimally invasive options to treat this aneurysm through the arteries had a low chance for success. The most effective option would have been cutting through the skull, preserving blood flow with a brain bypass to the distal artery, and clamping off the aneurysmal segment. With any brain surgery, there is a risk of major stroke or death, and in this gentleman's case, it would have been quite high. The newer alternative minimally invasive endovascular approach is typically performed through a catheter inserted in the groin or wrist. This additional tool can often reduce the chance of disability and death.

In 2011, the Pipeline Embolization Device was the first flow-diverter approved by the FDA. It is most similar to a vascular stent. While a stent resembles miniature chicken wire wrapped into a tube, the metal braids in a flow-diverter are much closer together – more similar to chainmail armor in a tube. This increased metal coverage can slow blood flow into the aneurysm so much that the blood becomes stagnant and clots which protects the patient from rupture. Over time, the clotted aneurysm outside the flow-diverter shrinks and morphs into dense connective tissue. Inside the artery, its innermost layer grows over the flow-diverter and incorporates it into the artery wall. Figure 2 demonstrates our 72-year-old's aneurysm before and after treatment.

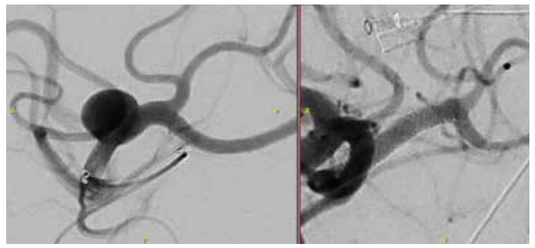

Figure 2. Left Image: Angiogram depicting the growing, fusiform left MCA aneurysm.
Right Image: Angiogram after treatment with a Pipeline flow-diverter. The Pipeline's "chainmail" appearance can be visualized spanning across the previously aneurysmal segment. No aneurysm remains. Good distal blood flow through both bifurcation branches persists.

AdventHealth was the first hospital in Central Florida to offer this revolutionary technology to our patients. Initial cases were limited to large aneaurysms in a proximal location. Over time, improvements in technology combined with local and worldwide clinical experiences have allowed application to a broadening number of complex cases like the one above.

For more information, please visit AdventHealthNeuroInstitute.com.